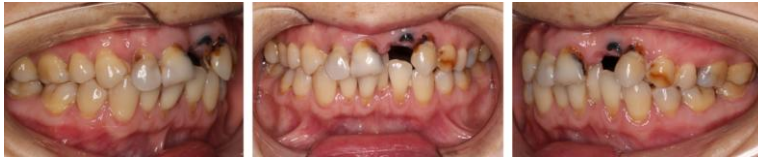
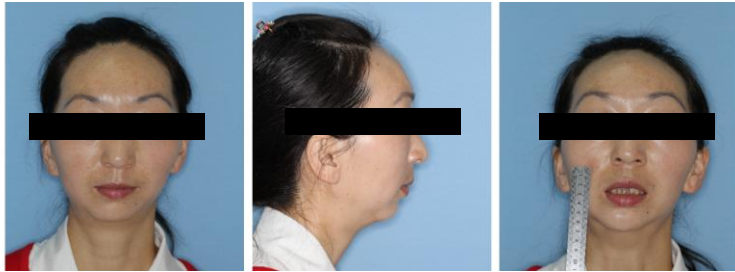
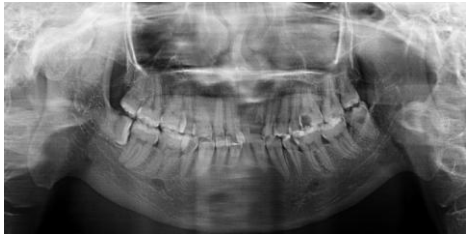# Joint ankylosis with deviated jaw deformity treated by orthognathic surgery + customized TMJ prosthesis

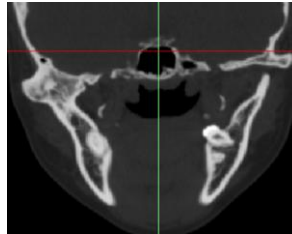
## Preoperative



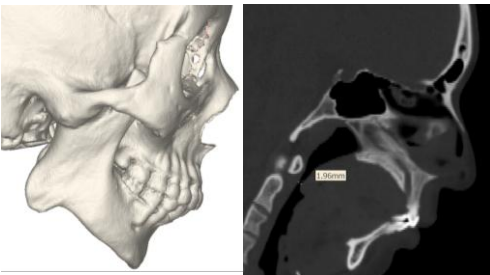Panoramic X-ray



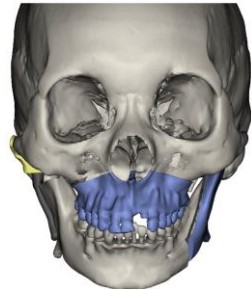
Preoperative CT



Preoperative CT

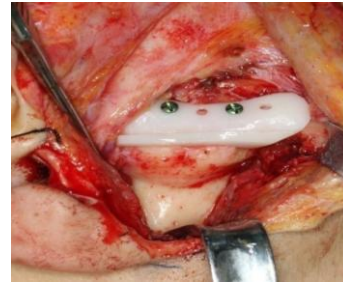


Surgical plan

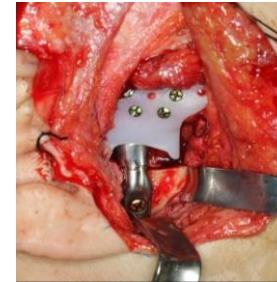


## Operation

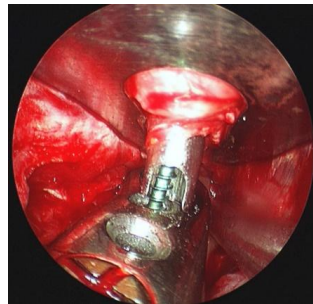
- ① A guide plate for removal of bone from the ankylosed right TMJ



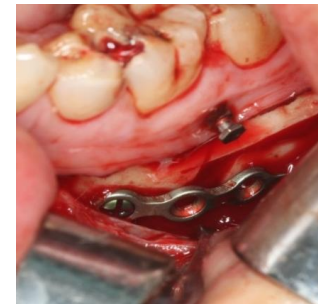- ② After sagittal osteotomy of the left ramus, the prosthesis was implanted



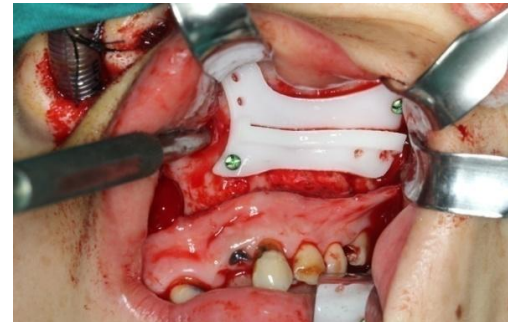- ③ Fixation of the condylar prosthesis with an endoscope



- ④ Plating of the left mandibular ramus osteotomy

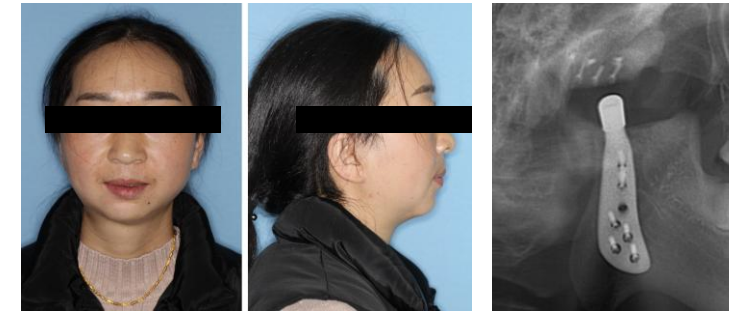


- ⑤ A cutting guide was used to create a precise Le Fort I osteotomy



## Postoperative

### One month after surgery



### Five years after surgery

